

# Endoscopic and Transconjunctival Orbital Decompression for Thyroid-Related Orbital Apex Compression

Steven D. Schaefer, MD; Peyman Soliemanzadeh, MD; David A. Della Rocca, MD; Gu-Pei Yoo, MD, PhD; Elizabeth A. Maher, MD; James P. Milite, MD; Robert C. Della Rocca, MD

**Objective:** To evaluate the efficacy and safety of a combined endoscopic and transconjunctival orbital decompression in patients with thyroid-related orbitopathy with orbital apex compression. **Study Design:** Retrospective review. **Methods:** A sequential series of patients with thyroid-related orbitopathy presenting with orbital apex compressive myopathy with and without optic neuropathy who were undergoing combined endoscopic and transconjunctival decompression by the same surgeons from 1992 to 2001 was reviewed. Patients were regularly evaluated preoperatively and postoperatively over a 3- to 55-month period to record the effects of this approach on visual acuity, Hertel exophthalmometry, and diplopia. Complications and secondary ophthalmological procedures were reviewed. **Results:** Between 1992 and 2001, 72 combined endoscopic and transconjunctival decompressions were performed on 41 patients with orbital apex compression. Visual acuity improved in 89.3% of the patients with compressive optic neuropathy ( $P < .0005$ ) and in 34.1% of those without neuropathy. Proptosis was reduced by 3.65 mm, on average. There was one case of transient intraoperative cerebrospinal fluid extravasation at the site of the optic nerve decompression, and one patient developed epistaxis. **Conclusions:** The study supports the treatment of thyroid-related orbital apex compression with and without compressive optic neuropathy by a combined transconjunctival and endoscopic approach. This approach offers short hospital stays, excellent visual recovery, and minimal complications in patients with thyroid-related orbital apex compressive myopathy and related compressive optic neuropathy. The beneficial effects observed in the patients with visual loss continued to im-

prove over time and were significant ( $P < .001$ ).  
**Key Words:** Thyroid-related orbitopathy, orbital apex compressive myopathy, compressive optic neuropathy, orbital decompression.

*Laryngoscope*, 113:508–513, 2003

## INTRODUCTION

Orbital manifestations develop in nearly half of all patients with Graves disease.<sup>1</sup> Yet, to date, the pathophysiology of thyroid-related orbitopathy has not been clearly elucidated, although autoimmunity against eye muscle and orbital fat antigens has been proposed.<sup>2–4</sup> Patients with TRO can have ocular findings ranging from mild exposure to acute vision loss, with up to 9% of patients developing compressive optic neuropathy (CON).<sup>5</sup> Because CON results from orbital apex compressive myopathy and is not related to exophthalmos, such patients may be unrecognized and their treatment delayed (Fig. 1). Interstitial edema, lymphocyte and mast cell infiltration, and mucopolysaccharide accumulation, especially in the extraocular muscles and retrobulbar fat, can result in compression of the optic nerve. When this occurs at the orbital apex, where there is limited cross-sectional area, patients may present with optic nerve dysfunction but with minimal proptosis. Clinically, in these patients with thyroid-related orbitopathy, exposure keratopathy can lead to corneal ulceration and chemosis. Restrictive ocular myopathy causing diplopia results from inferior and medial rectus muscle enlargement leading to restriction of globe movement. In the most severe cases, CON results from encroachment by the extraocular muscle mass on the optic nerve in the orbital apex. This manifests as dyschromatopsia, reduced brightness perception, decreased visual acuity, and visual field abnormalities. Therefore, knowledge of the natural history of this disease is crucial for surgeons caring for these patients.

Early in the course of thyroid-related orbitopathy, orbital manifestations often respond to high-dose steroid therapy. When this fails, external-beam irradiation may be considered.<sup>6</sup> However, when orbital involvement has been present for a long period, there is often fibrosis of the

From the Departments of Otolaryngology (S.D.S., P.S., G-P.Y.) and Ophthalmology (D.A.D.R., E.A.M., J.P.M., R.C.D.R.), The New York Eye and Ear Infirmary, New York Medical College, New York, NY, U.S.A.

Editor's Note: This Manuscript was accepted for publication October 21, 2002.

Send Correspondence to Steven D. Schaefer, MD, Department of Otolaryngology, The New York Eye and Ear Infirmary, 310 East 14th Street, New York, NY 10003, U.S.A. E-mail: sschaefer@nyee.edu

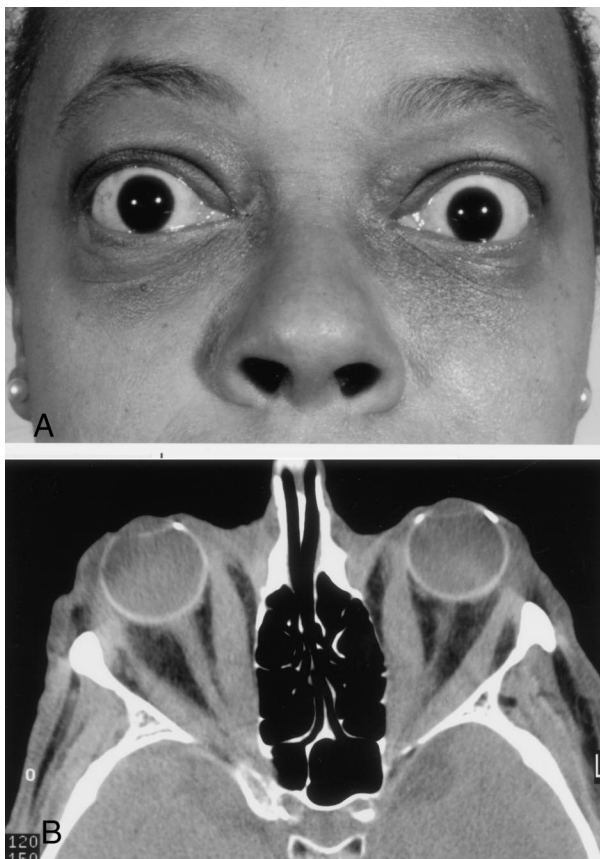


Fig. 1. (A) Patient with mild to moderate proptosis and acute vision loss secondary to thyroid-related orbitopathy. (B) Axial orbital computed tomography scan of same patient demonstrating significant optic compression and confirming bilateral proptosis.

involved tissues, and patients need surgical decompression followed by rehabilitative measures to correct diplopia, eyelid position, and appearance. The first surgical decompression of the orbit was a technique to gain lateral access to the orbit. Described initially by Kronlein in 1899 to remove orbital tumors, it was later used in 1911 by Dollinger to decompress the orbit in exophthalmos. Since 1957, the transantral decompression report of Walsh and Ogura<sup>7</sup> has represented the gold standard in such surgery. In 1990 and 1991, respectively, Kennedy et al.<sup>8</sup> and Michel et al.<sup>9</sup> reported the first series of intranasal endoscopic decompressions. They reported a comparable improvement in Hertel measurements with less morbidity than reported in previous large series. Similar results for entirely endoscopic decompressions were then reported by Metson et al.<sup>10</sup> and Lund et al.<sup>11</sup> Since then, several authors have begun to focus on the need for a more “balanced” decompression.<sup>12–15</sup> However, although a number of authors have focused on the effect of endoscopic decompression on thyroid-related orbitopathy, few of these reports have had significant numbers of patients with orbital apex compressive myopathy with or without CON.

The technique of combined endoscopic and transconjunctival decompression was first reported in 1997.<sup>16,17</sup> This procedure offers the advantages of both the intranasal endoscopic decompression of the medial orbital wall

and optic nerve and the more complete and safe access to the inferior wall provided by the transconjunctival approach. To validate combined transconjunctival and endoscopic decompression for the treatment of thyroid-related orbital apex compressive myopathy with and without optic neuropathy, we reviewed our experience in terms of 1) effectiveness of orbital decompression and, when indicated, optic nerve decompression, as measured by visual improvement; 2) complications and morbidity; and 3) duration of hospitalization. Although few reports have examined orbital apex compressive myopathy, we compare our results with those available in the literature.

## PATIENTS AND METHODS

Retrospective review of surgically treated patients with thyroid-related orbitopathy presenting to the New York Eye and Ear Infirmary (New York, NY) between 1992 and 2001 was performed. Although the present report is retrospective, patients’ management was prospectively performed based on early results between 1992 and 1994 treated by the senior authors (s.s., r.d.). All patients’ records were independently reviewed by other authors (P.S., D.D.) for previous conservative treatment with corticosteroids or radiotherapy, or both. The clinical course of these patients was reviewed to evaluate the effects of this approach on visual acuity, Hertel exophthalmometry, and diplopia. The occurrence of postoperative complications and secondary ophthalmological procedures were also reviewed. Statistical analysis was independently performed by the Department of Otolaryngology epidemiologist (G-P.Y.).

### *Selection Criteria for Surgical Management*

To be considered for surgical treatment, the patient must have a combination of 1) rapidly decreasing vision with CON confirmed by computed tomograph (CT) or magnetic resonance imaging (MRI) scan, 2) progressive ophthalmoplegia refractive to high-dose steroids, 3) exposure keratopathy in which an eyelid operation was not deemed to be adequate, 4) visual field abnormalities, 5) acquired dyschromatopsia, or 6) afferent pupillary defect (APD). A diagnosis of CON was made by consideration of the following findings: 1) decrease in visual acuity not explained by the refractive state or anterior segment findings, 2) defective visual fields with no prior record of glaucoma or other medical history, 3) presence of optic disc congestion or signs of retrobulbar compression, 4) radiographic confirmation of compressive neuropathy, 5) acquired dyschromatopsia, and 6) APD. Diagnostic evaluations, including MRI or CT scans of the sinuses and orbits were reviewed by the senior authors (s.s., r.d.) to rule out sinusitis and to document compression of the optic nerve.

### *Surgical Technique*

With the patient under general anesthesia, the nose was vasoconstricted using oxymetazoline-saturated cottonoid pledgets and injection of 1% lidocaine with 1:100,000 epinephrine into the lateral nasal wall. Total intranasal endoscopic ethmoidectomy and middle meatus antrostomy were performed as previously described.<sup>18</sup> In patients with CON (and therefore undergoing optic nerve decompression), sphenoidotomy with complete removal of the anterior sphenoid face was performed before the retrograde exenteration of superior ethmoid cells. To avoid occlusion of the antrostomy by prolapsing orbital soft tissue from the floor decompression, a large antrostomy was routinely included in the surgical management. The entire medial orbital wall was removed anterior to the sphenoid, inferior to the frontal, posterior to the lacrimal, and superior to the maxillary bones. Wall removal was begun in the mid orbital plane with microcurette or freer

elevator, and was continued posteriorly and then anteriorly. Three posterior-to-anterior radial incisions were made in the periorbita. The periorbita was gently manipulated to encourage fat extrusion into the ethmoid sinus. In patients undergoing optic nerve decompression, the medial wall of the sphenoid sinus anterior to the internal carotid artery was removed with self-irrigating diamond burr to permit bony decompression of the medial optic foramen before incising the periorbita. The optic nerve sheath was not incised (except in one case). One neurosurgical cottonoid pledget was placed in the ethmoid cavity for packing and removed the following morning.

Following the endoscopic procedures, the lower eyelid and lateral canthus were infiltrated with 1% lidocaine with 1:100,000 epinephrine. Lateral canthotomy followed by cantholysis was performed. The lower lid was everted, and the conjunctiva and retractor muscle were incised 6 mm below the limbus centrally. Dissection was continued between the orbicularis muscle and orbital septum to the orbital rim. Care was taken to keep the orbital septum intact to avoid premature fat herniation. Protecting the orbital contents, an incision was made 2 mm below the orbital rim allowing access to the floor of the orbit. Following this, relaxing incisions were made in the periosteum. An osteotome was used to fracture the inferior wall medial to the infraorbital nerve. Using a Kerrison rongeur, bony removal was performed in small bites without twisting. Bony dissection then proceeded medially until the decompression from the previous endoscopic procedure was encountered. A lateral portion of the inferior orbital wall may have been removed if the infraorbital canal ran medially. The posterior limit of the dissection was the posterior wall of the maxillary sinus. A strut of bone at the junction of the medial wall and inferior wall was left intact to supply support for the globe. Lower-eyelid retractors and conjunctiva were closed with 6-0 plain or chromic sutures. The lateral edge of the canthal tendon was attached to the periorbita using 4-0 Polydek suture. The lateral skin incision was closed with interrupted 6-0 sutures. The traction sutures and corneal shield were removed and the eye was dressed with an antibiotic ointment and a bandage.

## RESULTS

Since 1992, 162 patients had undergone surgical treatment for thyroid-related orbitopathy. Excluded from the present report were patients with incomplete or unavailable medical records, patients treated by other surgeons, and patients without orbital apex compressive myopathy. Forty-one patients met these criteria for inclusion

in the present report, with 72 eyes in all undergoing endoscopic and transconjunctival decompression for orbital apex compression. Twenty-eight of the 72 eyes also had CON as previously defined in the present report, and their treatment included sphenoidotomy with removal of medial wall of optic canal for nerve decompression. All 41 patients were noted to have orbital apex compression on CT and/or MRI scanning as reviewed by the senior authors (S.S., R.D.). All patients had received high-dose steroids before surgical decompression. The average hospital stay was 1 day.

Within the present group of 41 patients, there were 25 women and 16 men. The patients ranged in age from 20 to 80 years; mean age was  $50 \pm 19.4$  years (mean  $\pm$  standard deviation [SD]). Follow-up ranged from 3 to 55 months postoperatively. Of these 72 eyes, combined transconjunctival and intranasal decompression with optic nerve decompression was performed on 16 patients (28 eyes) for CON (39%) as previously defined in our methodology. The other 25 patients (44 eyes) had orbital apex compressive myopathy without vision loss (61%), and with the exception of one patient with severe muscle crowding within the orbital apex, none of these patients underwent optic nerve decompression.

Table I shows the mean percentage of change in visual acuity preoperatively and during the postoperative course in patients with and without CON. Among the patients with CON, 14 patients had acute vision loss (25 eyes) and 2 patients had decreased color plates (3 eyes) as their primary indication for decompression of the orbit and optic nerve. No patients had visual field defects or afferent pupillary defects as their primary indication. However, of those with vision loss as their primary indication, three eyes (two patients) were also noted to have APD and one patient had visual field defects. In patients who had more than one indication for decompression, vision loss, when present, was considered the primary indication for surgery.

Vision improvement occurred in 25 of the 28 eyes (89%) undergoing decompression for CON (Table II). This improvement was noted to continue to progress signifi-

TABLE I.  
Mean Percentage Change in Visual Acuity During the Postoperative Course in a Subset of Patients With Compressive Optic Neuropathy Compared With a Subset Without Preoperative Vision Loss.

Time Periods	Patients With Preoperative Compressive Neuropathy			Patients Without Preoperative Compressive Neuropathy		
	No.	Visual Acuity* (mean $\pm$ SD)	Change Percentage† (mean $\pm$ SD)	No.	Visual Acuity* (mean $\pm$ SD)	Change Percentage† (mean $\pm$ SD)
Preoperation	28	231.96 $\pm$ 263.52	—	44	54.30 $\pm$ 146.40	—
Postoperation visit	28	176.61 $\pm$ 245.94	-4.21 $\pm$ 83.68	44	67.48 $\pm$ 148.67	43.52 $\pm$ 108.03
One-month visit	28	58.93 $\pm$ 70.44	-50.08 $\pm$ 35.50	44	55.20 $\pm$ 146.03	8.26 $\pm$ 29.86
Final visit	28	51.43 $\pm$ 70.88	-57.98 $\pm$ 32.28	44	52.25 $\pm$ 146.40	-0.74 $\pm$ 25.75
		$\chi^2$ Friedman = 58.97, df = 3, $P < .001$			$\chi^2$ Friedman = 18.408, df = 3, $P < .001$	

\*Vision measured at a distance of 20 feet; eg, the upper left-hand column refers to 20/231.96 mean vision for this group of patients with a standard deviation of 263.52.

†The visual acuity change percentage was calculated by (following visit's visual acuity value - preoperation visual acuity value)  $\div$  preoperation visual acuity value  $\times$  100.  
SD = standard deviation.

TABLE II.  
Percentage Change in Visual Acuity Lines During Postoperative Course.

	Vision Loss at Preoperation		Not Vision Loss at Preoperation	
	No. (28)	Percent	No. (44)	Percent
Postoperation visit				
Visual lost	5	(17.9)	18	(40.9)
No vision change	9	(32.1)	22	(50.0)
1–5 lines improved	13	(46.4)	4	(9.1)
≥6 lines improved	1	(3.6)	0	(0.0)
One-month visit				
Visual lost	1	(3.6)	15	(34.1)
No vision change	3	(10.7)	21	(47.7)
1–5 lines improved	15	(53.6)	7	(15.9)
≥6 lines improved	9	(32.1)	1	(2.3)
Final visit				
Visual lost	1	(3.6)	6	(13.6)
No vision change	2	(7.1)	23	(52.3)
1–5 lines improved	13	(46.4)	14	(31.8)
≥6 lines improved	12	(42.9)	1	(2.3)

Note: Fisher's exact test (two-tailed): Vision loss at preoperation: postoperation vs. 1-month visit:  $P = .00527$ ; postoperation vs. final visit:  $P = .000454$ . 1-month visit vs. final visit:  $P = .857$ .

Not vision loss at preoperation: postoperation vs. 1-month visit:  $P = .578$ ; postoperation vs. final visit:  $P = .00287$ . 1-month visit vs. final visit:  $P = .063$ .

cantly at each subsequent follow-up ( $P < .0005$ ). However, continued vision loss was observed in one patient (one eye), and no improvement in vision was seen in one patient (two eyes). The loss of vision was one line (20/300 changed to 20/400) in this former patient. Of note, 42.9% (12 eyes) were found to have greater than six lines of vision improvement.

In the 44 eyes with orbital apex myopathy without CON (Table I), the indications for surgery included 25 eyes with severe exposure keratopathy, 17 eyes with restrictive myopathy, and 2 eyes with increased ocular pressure. When keratopathy and myopathy were both present, keratopathy was considered the primary indication for study purposes. No patients were included in the present report with cosmesis as their primary surgical indication. Within the patients who did not have preoperative vision loss, 38 eyes (86.4%) had either no change or improvement in their vision postoperatively (Table II). As was observed in the patients with CON, significant vision improvement continued with each subsequent follow-up visit ( $P < .003$ ). Fifteen eyes were noted to have improved vision postoperatively (34.1%), whereas the other 23 eyes (54.5%) had no change in vision following decompression. One patient had greater than six lines of improvement. Of the remaining six eyes (four patients) with postoperative vision loss, the average loss was only 1.2 lines (range, 1–2 lines).

The average preoperative Hertel measurement for all patients was  $25.40 \pm 2.84$  mm (mean  $\pm$  SD; Table III). There was no statistical difference in average Hertel measurements or in amount of decompression between pa-

TABLE III.  
Hertel's Measurements in Millimeters Preoperatively, at 1-Month Follow-up, and at Final Visit.

	Vision Loss at Preoperation		Not Vision Loss at Preoperation	
	No.	Mean $\pm$ SD	No.	Mean $\pm$ SD
Preoperation	26	$25.23 \pm 2.37$	42	$25.50 \pm 3.12$
Postoperation visit				
One-month visit	26	$21.62 \pm 2.67$	41	$22.61 \pm 3.33$
Final visit	26	$21.27 \pm 2.43$	41	$22.05 \pm 3.10$

SD = standard deviation.

tients who had preoperative vision loss and those who did not. Changes in proptosis measured by Hertel exophthalmometer at the 1-month postoperative visit showed an average decrease of  $3.2 \pm 3$  mm (mean  $\pm$  SD). The overall reduction in protrusion of the orbit was  $3.65 \pm 2.9$  mm (mean  $\pm$  SD). There was no difference in decompression in patients with CON as their indication for surgery when compared with patients without CON. No correlation was found between recession in the Hertel measurements and improvement in visual acuity.

Twenty patients (48.8%) complained of diplopia preoperatively. However, four of these patients had resolution of their diplopia postoperatively. Another five patients complained of new diplopia postoperatively, with three of them having resolution over their postoperative course without further surgical intervention. Fifteen of the 18 patients with prolonged diplopia required strabismus surgery after decompression.

Complications encountered included one patient with transient intraoperative cerebrospinal fluid extravasation secondary to removing bone surrounding the medial aspect of the optic nerve. No further treatment of this patient was required. There were no cases of dacryostenosis or ocular motility disturbance caused by extraocular eye muscle injury. No patients developed postoperative orbital infections or sinusitis. No patient required blood transfusion, and average blood loss was less than 50 mL per eye for all procedures. There were two patients who had preoperative chronic sinusitis, and both had endoscopic sinus surgery to address the affected sinuses at the time of decompressive surgery. There was one case of intraoperative epistaxis, which resolved by placement of a Merocel sponge, which was removed within 24 hours.

## DISCUSSION

In the earliest series of patients undergoing decompressive surgery, the primary indication had been visual deficit. With the advent of safer approaches, the perception that in experienced hands surgical decompression is a safe operation has led to increasingly earlier intervention in thyroid-related orbitopathy, with cosmesis and proptosis becoming a primary indication in many cases. Until recently, the mainstay of surgical decompression for thyroid ophthalmopathy has been the removal of the medial wall and the bony orbital floor through the transantral approach described by Walsh and Ogura<sup>7</sup> in 1957. Since

1991, our attention has focused increasingly on endoscopically assisted orbital decompression, as described first by Kennedy et al.<sup>8</sup> and shortly thereafter by Michel et al.,<sup>9</sup> Metson et al.,<sup>10</sup> and Lund et al.<sup>11</sup> However, although a number of reports have focused on the effect of endoscopic decompression on thyroid-related orbitopathy, few of these reports have had significant numbers of patients with orbital apex compression or CON.

In one series of 428 patients who had decompression surgery for severe ophthalmopathy, Garrity et al.<sup>19</sup> had found that of the patients with less than 20/20 vision, approximately 65% of patients had improved visual acuity postoperatively using the transantral approach. However, the average hospital stay ranged from 2½ to 4 days, with complications including cerebrospinal fluid leaks in 3.5% of their patients and intraoperative blood loss requiring transfusions in 11 patients. More recently, Michel et al.<sup>20</sup> found that visual acuity in 61 patients with CON undergoing intranasal endoscopic decompression increased from a preoperative average of  $0.50 \pm 0.27$  to  $0.75 \pm 0.21$  (mean  $\pm$  SD) postoperatively, with only four patients requiring repeat intervention for vision loss. The average hospital stay for the entire group of patients was 6 days.

In the present study, we found that visual improvement occurred in 89% of the eyes decompressed for CON ( $P < .0005$ ), with a remarkable 43% having greater than six lines of vision improvement. Further, visual acuity improved in 34% of the 44 eyes with orbital apex compression without CON. This visual improvement reflects resolution of refractive changes in the anterior chamber of the eye after orbital decompression. These results compare favorably with the previously aforementioned studies. Also important are the short hospital stay and minimal complications in our series.

In our study, we found no difference in the mean preoperative Hertel measurement in patients presenting with orbital apex compression with CON and patients who did not have vision loss. The mean reduction in proptosis after decompression in our patients was similar to that in some studies,<sup>15,20,21</sup> but significantly less than that of other authors who have reported reductions ranging from 4.5 to 5.7 mm.<sup>1,8,10,11,13,14,16,19</sup> The importance of this is that our data corroborate the finding of Michel et al.<sup>20</sup> that there was no correlation between recession in the Hertel measurement and improvement in visual acuity. This is especially important in light of the fact that the mean preoperative Hertel measurement in our series was significantly larger than many of the previously published reports. In our opinion, these data further crystallize the crucial role that is played by decompression of the orbital apex and the role of the endoscope in this decompression.

The endoscopic approach provides optimal decompression of the optic nerve in cases of optic neuropathy. Visualization of the medial orbital wall is superior to either the transantral or the external ethmoid approach. This approach permits a maximal posterior orbital decompression at the orbital apex, an area not fully accessible through the transantral routes. Optic nerve decompression for CON in thyroid-related orbitopathy is not frequently performed; therefore, we do not have a similar series of patients to compare with our results. We elected

to remove the medial bony wall of the optic canal without altering the optic nerve or its sheath in patients with CON in the hope that neural function would be more likely to improve. Aside from our results, we have no other way to support this procedure as a recommended part of the treatment of CON. Other advantages of the endonasal approach include safer and more precise bone removal and lessened postoperative sinus and orbital morbidity, compared with external ethmoidectomy or transantral surgery. As with previous other reports using the endoscopic approach, we found no dysesthesia of the infraorbital nerve, no dental problems, and no cosmetic problems associated with incisions. However, because the endoscopic approach does not allow for adequate exposure of the lateral orbital floor, the infraorbital nerve is at increased risk and adequate removal of the orbital floor is not possible. We used the transconjunctival approach to balance the shortcomings of the endoscopic approach.

The transconjunctival approach offers good floor exposure but has shortcomings in the medial wall, particularly in the crucial area of the apex. Therefore, the infraorbital nerve is protected in this combined technique, and the orbital floor is sufficiently exposed. Furthermore, intranasal middle meatus antrostomy is performed during the endoscopic approach, which in our series successfully prevented postoperative sinusitis. This is a shortcoming of the transconjunctival approach because of prolapsed orbital contents obstructing the maxillary sinus ostium. The technique of combined decompression offers a blend of the advantages of both.

## CONCLUSION

The present study supports the treatment of thyroid-related orbital apex compression with and without CON by a combined transconjunctival and intranasal endoscopic approach. The importance of the orbital apex in vision loss and the role of the endoscope in decompression of the apex for return of vision are verified. With short hospital stays, excellent visual recovery, and almost no complications, our data support the trend toward the use of the endoscopic approach in patients with severe ophthalmopathy. The beneficial effects observed in patients with vision loss continued to improve with follow-up and were highly significant.

## BIBLIOGRAPHY

1. Weisman RA, Osguthorpe JD. Orbital decompression in Graves' disease. *Arch Otolaryngol Head Neck Surg* 1994; 120:831-834.
2. Konishi J, Herman M, Kriss JP. Binding of thyroglobulin and thyroglobulin-antithyroglobulin immune complex to extraocular muscle membrane. *Endocrinology* 1974;95: 434-466.
3. Weetman AP. Thyroid associated eye disease: pathophysiology. *Lancet* 1991;338:25-26.
4. Atabay C, Tyutyunikov A, Scalise D, et al. Serum antibodies reactive with eye muscle membrane antigens are detected in patients with nonspecific orbital inflammation. *Ophthalmology* 1995;102:145-153.
5. Rootman J. Graves orbitopathy. In: Rootman J, ed. *Disease of the Orbit*. Philadelphia: JB Lippincott, 1988:24-280.
6. Petersen IA, Kriss JP, Donaldson SS. Prognostic factors in the radiotherapy of Graves' ophthalmopathy. *Int J Radiat Oncol Biol Phys* 1990;19:259-264.

7. Walsh TE, Ogura JH. Transantral orbital decompression for malignant exophthalmos. *Laryngoscope* 1957;67:544–549.
8. Kennedy DW, Goldstein ML, Miller NL, et al. Endoscopic transnasal orbital decompression. *Arch Otolaryngol Head Neck Surg* 1990;116:275–282.
9. Michel O, Bresgen K, Russman W, et al. Endoskopisch kontrollierte endonasale orbitadekompression beim malignen ophthalmus. *Laryngorhinootologie* 1991;70:656–662.
10. Metson R, Dallow RL, Shore JW. Endoscopic orbital decompression. *Laryngoscope* 1994;104:950–957.
11. Lund VJ, Larkin G, Fells P, et al. Orbital decompression for thyroid eye disease: a comparison of external and endoscopic techniques. *J Laryngol Otol* 1997;111:1051–1055.
12. Leone CR, Piest KL, Newman RJ. Medial and lateral wall decompression for thyroid ophthalmopathy. *Am J Ophthalmol* 1989;108:160–166.
13. Goldberg RA, Rotman J, Stuart B. In: *Orbital Surgery: A Conceptual Approach*. Philadelphia: Lippincott-Raven, 1995:362–363.
14. Shepard KG, Levin PS, Terris DJ. Balanced orbital decompression for Graves' ophthalmopathy. *Laryngoscope* 1998;108:1648–1653.
15. Lyons CJ, Rootman J. Orbital decompression for disfiguring exophthalmos in thyroid orbitopathy. *Ophthalmology* 1994;101:223–230.
16. Graham SM, Carter KD. Combined endoscopic and subciliary orbital decompression for dysthyroid compressive optic neuropathy. *Rhinology* 1997;35:103–107.
17. Sillers MJ, Cuilty-Siller C, Kohn FA, et al. Transconjunctival endoscopic orbital decompression. *Otolaryngol Head Neck Surg* 1997;117:5137–5141.
18. Schaefer SD. An anatomic approach to endoscopic intranasal ethmoidectomy. *Laryngoscope* 1998;108:1628–1634.
19. Garrity JA, Fatourehchi V, Bergstralh EJ, et al. Results of transantral orbital decompression in 428 patients with severe Graves' ophthalmopathy. *Am J Ophthalmol* 1993;116:533–547.
20. Michel O, Oberlander N, Neugebauer P, et al. Follow-up of transnasal orbital decompression in severe Graves' ophthalmopathy. *Ophthalmology* 2001;108:400–404.
21. Carter KD, Frueh BR, Hessburg TP, et al. Long term efficacy of orbital decompression for compressive optic neuropathy of Graves' eye disease. *Ophthalmology* 1991;98:1435–1442.